

Preparation of the Root Canal System

This material is provided for information and education purposes only. No doctor/patient relationship has been established by the use of this site. No diagnosis or treatment is being provided. The information contained here should be used in consultation with an endodontist/dentist of your choice. No guarantees or warranties are made regarding any of the information contained within this website. This website is not intended to offer specific medical, dental or surgical advice to anyone. Dr. Crumpton is licensed to practice in Mississippi, and this website is not intended to solicit patients from other states. Further, this website takes no responsibility for web sites hyper-linked to this site and such hyper-linking does not imply any relationships or endorsements of the linked sites.

INTRODUCTION

Schilder H. Cleaning and shaping the root canal. Dent Clin North Am 1974;18:269-96.

- ◆ Each root canal system is different from another; therefore, no two root canal preparations should be exactly alike. Certain constant principles for cleaning and shaping, however, are carried out in every case:
- ◆ The root canal preparation should develop a continuously tapering funnel from the root apex to the coronal access cavity.
- ◆ The cross-sectional diameter of the preparation should be narrower at every point apically and wider at each point as the access cavity is approached.
- ◆ The preparation should occupy as many planes as are presented by the root and the canal. The preparation should *flow* with the shape of the original canal.
- ◆ The apical foramen should remain in its original spatial relationship both to the bone and to the root surface.

The apical opening should be kept as small as is practical in all cases.

Ruddle C. Cleaning and shaping the root canal system. In Cohen S, Burns RC (eds). Pathways of the pulp. 8th ed. St. Louis: CV Mosby Company, 2002:231-273.

Clinical Objectives: “Start with the end in mind”

- ◆ Pretreatment – ensure restorability
- ◆ Access for Success – remove the pulpal roof entirely, obtain straight line access, visualize all orifices without moving the mouth mirror, achieve axial walls with adequate taper and access the canals.

Mechanical Objectives:

- ◆ Continuously tapering preparation from the chamber to the foramen.
- ◆ Maintain original anatomy, consider curvatures and root concavities.
- ◆ Maintain the position of the foramen.
- ◆ Keep the foramen as small as practical. The foramen is circular shaped therefore doubling the file size increases the diameter fourfold. (pr^2)

Concepts and Strategies for Canal Preparation:

The majority of teeth range from 19-25mm, the crown is usually about 10mm, therefore the root lengths range from 9-15mm. This length can be divided into thirds; coronal, middle and apical.

- ◆ Coronal 2/3rds Preenlargement:
 - Increases tactile perception and control of the apical third.
 - Enhances cleaning by allowing a greater volume of irrigant in the canal.
 - Removes the bulk of debris, decreasing irritants potentially pushed past the apex.

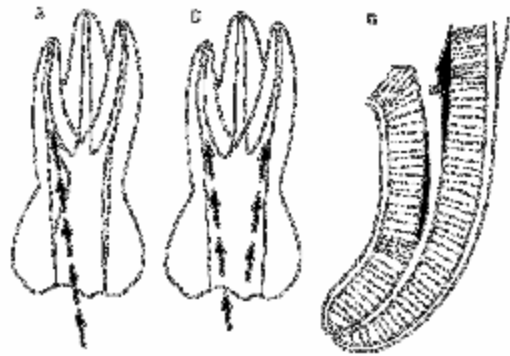
- ◆ Apical 1/3rd Finishing:
 - Scout the terminus – small files and radiographs will confirm the anatomy prior to any iatrogenic mishaps.
 - Establish patency, avoid packing the apical terminus with dentinal mud.

Establish working length with both EAL's and radiographs.

Walton RE, Rivera EM. Cleaning and shaping. In Walton RE, Torabinejad M (eds). Principles and Practice of Endodontics. 2nd ed. Philadelphia: WB Saunders, 1996:181-233.

1. Major objectives of access preparation

- ◆ Straight-line access into the canal system and complete unroofing of the pulp chamber, this aspect is often neglected in anterior teeth.
- ◆ Removal of all caries and defective restorations
- ◆ Creation of divergent walls to provide a positive seat for the temporary restoration and to maximize direct visibility of the canal system
- ◆ Conservation of tooth structure



2. Special considerations during access preparation

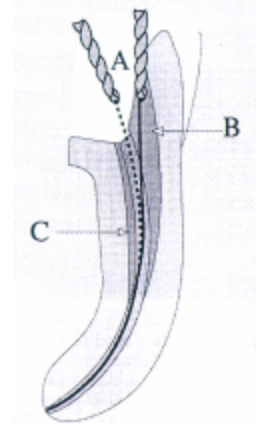
- ◆ **Caries, defective restorations, and unsupported tooth structure:** These problems should be addressed during the access phase and may require temporary placement of restorative materials. Removal of restorative materials should be accomplished prior to canal access to avoid particles from blocking the canals or being forced out the apex.
- ◆ **Extensive restorations and prosthetic restorations:** These may change the position or long axis of the tooth. Removal of large restorations may aid access but present additional concerns for tooth isolation. Consider access preparation prior to rubber dam placement as a visual aid to prevent disorientation.
- ◆ **Calcified canals:** Placement of the rubber dam can be delayed until difficult to locate canals have been identified, this allows the operator to utilize the long axis of the tooth to improve orientation.

3. Problems associated with inadequate access preparations:

- ◆ Unnecessary loss of healthy tooth structure
- ◆ Residual caries and defective restorations
- ◆ Poor access and visibility of the canal system
- ◆ Inadequate instrumentation and obturation of canal system
- ◆ Perforations
- ◆ Postoperative pain

Swindle R, Neaverth E, Pantera E, Ringle R. Effect of coronal-radicular flaring on apical transportation. J Endodon 1991; 17(4):147-149.

The purpose of this study was to evaluate the effect early and late radicular flaring (no flaring was done) has on apical canal transportation when using balanced force instrumentation. While early radicular flaring made instrumentation easier, no significant differences were found when comparing apical transportation between the two groups when balanced force technique was used.



Stabholz A, Rotstein I, Torabinejad M. Effect of preflaring on tactile detection of the apical constriction. J Endodon 1995; 21(02): 92-94.

The ability to determine the apical constriction by tactile sensation was significantly increased when the canals were preflared. It was possible to detect the apical constriction in the preflared group by tactile sensation in 75% of the time vs. 32.3% in the nonflared group.

APICAL SHAPE

The shape of the last few millimeters of the canal system is critical. A tapering funnel shape allows adequate cleaning and distortion of obturation materials by compacting. Ideally, the apical extent of the canal system should be clean, patent, and completely obturated. The shape and position of the apical foramen should remain unchanged.

PATENCY OF THE APICAL FORAMEN

Patency means that the apical constriction is open; that is, it is not blocked with debris. A radiograph with a “patency file” in place helps to precisely identify the location of the portal of exit. Patency of the apical foramen should be preserved throughout the process of cleaning and shaping the canal system.

DETERMINE A WORKING LENGTH

The working length is defined as the distance from a coronal reference point to a point at which canal preparation and obturation should terminate. Cleaning and shaping can only be as precise as the working length determination. The most clinically relevant landmark is the apical constriction, whether in dentin or cementum. This has the narrowest diameter of the canal thus the most rational point at which to terminate canal preparation.

Methods of canal length determination

- ◆ Dental morphology – average tooth length
- ◆ Radiographic – the most commonly used method, may require multiple angles, and changes of >1.0mm should be verified with additional radiographs
- ◆ Electronic – apex locators will be addressed in the next seminar
- ◆ Paper point evaluation – following instrumentation

Tactile – with experience the clinician can gain considerable information from the passage of an instrument through the canal.

Wu M-K, Barkis D, Roris A, Wesselink PR. Does the first file to bind correspond to the diameter of the canal in the apical region? Int Endodon J 2002;35:264-267.

- ◆ Both K-files and modified Lightspeed instruments were inserted to the length at which binding occurred.
- ◆ The apical tooth structure was removed to expose the instrument.
- ◆ 75% of the first instruments that bound in canals at working length were contacting only one wall; the other 25% did not contact any walls. The first file to bind does not reflect the canal diameter at working length.

Burch JG, Hulen S. The relationship of the apical foramen to the anatomic apex of the tooth root. Oral Surg 1972;34:262-8.

92.4% of the major foramina of all classes of teeth deviated from the anatomic apex. The average distance between the foramen and the anatomic root apex was 0.59mm.

Stein TJ, Corcoran JF. Anatomy of the root apex and its histologic changes with age. Oral Surg 1990;69:238-42.

Distance from the major diameter (apical foramen) to the CDJ - 0.72 mm. Width of the CDJ - 0.189 mm (~ size of a 20 file) Width of the major diameter - 0.54 mm. As age increases, the deviation of the foramen from the apical center and its width increases as a result of increased apical cemental deposition.

Wu M-K, Wesselink PR, Walton RE. Apical terminus location of root canal procedures. Oral Surg Oral Med Oral Pathol Oral Radiol Endod 2000;89:99-103.

This literature review indicates that based on biological principles and experimental evidence, instrumentation or obturation should not extend beyond the apical foramen.

INSTRUMENTATION PROCEDURES

Walton RE, Rivera EM. Cleaning and shaping. In Walton RE, Torabinejad M (eds). Principles and Practice of Endodontics. 3rd ed. Philadelphia: WB Saunders, 2002:206-238.

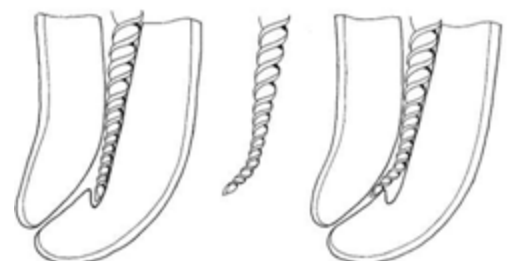Apical Preparation

- ◆ Confines instrument, materials, and chemicals to the canal space
- ◆ Creates a barrier against which gutta-percha can be compacted.
- ◆ Apical stop: a barrier which cannot be penetrated.
- ◆ Apical seat: lack of a complete barrier, but the presence of a constriction.
- ◆ Open apex: resembles an open cylinder, will not confine material to the canal space.



Anatomic Aberrations

- ◆ Irregular anatomical regions containing tissue, these are relatively inaccessible to instrumentation and represent a potential cause for long-term failure.
- ◆ These may present as intercanal isthmi, cul-de-sacs, lateral canals, and apical ramifications. The prevalence of these occurrences increases in posterior teeth.



- ◆ These may be addressed through frequent irrigation and chemical debridement.

Ledge Formation

- ◆ The greater the degree of curvature the greater the chance of straightening the canal.
- ◆ Original length can sometimes be regained by placing a bend in the apical 1-2mm of a small file in order to probe the apical walls and locate the original canal curvature.

1. Canal curvature

- ◆ As an instrument curves, elastic forces (ie. restoring forces) attempt to return the instrument to its original shape and are responsible for straightening the canal. Elastic forces are most powerful at the junction of the instrument tip and its cutting edges.
- ◆ The cutting edge of the instrument is the most efficient point along the instrument and therefore removes the most tooth structure.
- ◆ The angle of deflections, size of the instrument, and rigidity of the instrument all increase the power of the file to instrument in the canal.



2. Canal transportation

Removal of canal wall structure on the outside curve in the apical half of the canal due to the tendency of the files to regain their original linear shape during canal preparation.

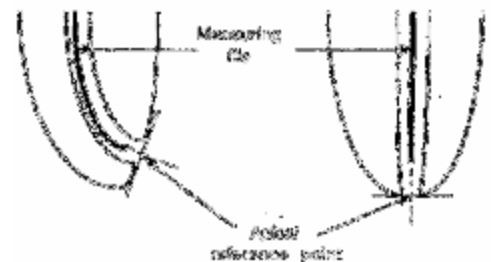
3. Apical zipping

Instrumentation of the apical foramen can convert a round apical foramen into a teardrop shape or zip. The zipped area retains tissue and dentin debris and obturation cannot seal the resulting shape.



Elayouti A, Weiger R, Lost C. Frequency of overinstrumentation with an acceptable radiographic working length. J Endodon 2001;27:49-52.

- ◆ The results of the 30 anterior teeth demonstrated no instances in which the radiographic working length was beyond the foramen.
- ◆ However, in the premolar group (43 teeth) 51% of the files were placed past the foramen and 22% of the molar group (96 canals) had similar results.
- ◆ Radiographic working lengths in premolars and molars that appear 0-2mm short of the radiographic apex may result in unintentional overinstrumentation.




4. Canal ledges

Continuous instrumentation to the same depth can straighten the canal and form a ledge that prevents further passage of the file.



5. Apical perforations

A new portal of exit can be created if incorrect instrumentation is used when the apical third of the canal is curved. Blockage of the canal with dentin mud or forceful attempts to bypass a ledge can lead to this mishap.

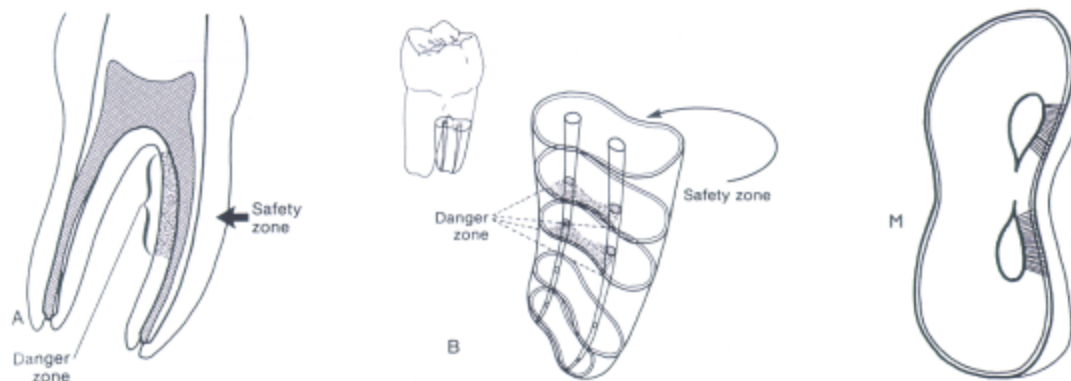


6. Strip perforations

- ◆ The cervical portion of the instrument straightens the canal in multirooted teeth, leading eventually to communication with the furcation.
- ◆ In the danger zone there is less tooth structure compared with the more peripheral portion (safety zone) or the root dentin.

Berutti E, Fedon G. Thickness of cementum/dentin in mesial roots of mandibular first molars. J Endodon 1992;18(11):545-8.

Root structure is only 1.2-1.3mm thick along the distal wall of the mesial root of mandibular molars 1.5mm below the furcation.



INSTRUMENT TYPES AND USES

Schafer E. Root canal instruments for manual use: a review. Endod Dent Traumatol 1997;13: 51-64

Reviews the different types of hand instruments available according to alloy composition and geometric configuration.

- ◆ K-reamers are more flexible and fracture resistant but offer no advantages to K-files.

- ◆ Hedstrom files are preferred for maximum cutting efficiency when enlarging the straight coronal portion of a canal. Safety Hedstrom files have a non cutting surface to prevent ledging in curved canals.
- ◆ Flexible SS files with a non-cutting tip are superior to conventional SS files, NiTi files, or NiAl files when compared by cutting efficiency and instrumentation of curved canals.
- ◆ Half-sized instruments from #12-#37 can be helpful in narrow sclerotic canals.
- ◆ No file produces an entirely centered enlargement of the curved canal.
- ◆ No individual file or filing system is superior and it is up to the provider to judge each case individually and take advantage of the system that meets that particular need.

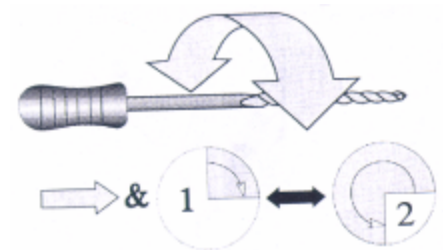
Balanced force

Balanced force motion is a most effective way to cut dentin.

- ◆ Instrument is rotated clockwise one quarter turn with gentle inward pressure to pull file into canal and engage dentin surface.
- ◆ Instrument is rotated counter-clockwise (one third to two full turns) with apical pressure to shear off dentin.
- ◆ A passive non-cutting clockwise rotation loads newly cut dentin into file flutes.
- ◆ Instrument and loaded debris are removed from canal.

Roane JB, Sabala CL, Duncanson MG. The "balanced force" concept for instrumentation of curved canals. J Endodon 1985;11:203-11.

Rationale and technique of balanced force technique is presented. Flex-R (*alternate is Flexofile – Dentsply Maillefer*) files with non-cutting tip are used. Control the restoring forces exerted by the instrument by modifying the reaming technique so curved canals can be enlarged without transportation.



Sepic AO, Pantera EA, Neaverth EJ, Anderson RW. A comparison of flex-R files and K-type files for enlargement of severely curved molar root canals. J Endodon 1989;15:240-6.


The balanced force technique using Flex-R files results in significantly less apical canal alteration than the step-back technique using K-type files in curved canals.

Wu MK, Wesselink PR. Efficacy of three techniques in cleaning the apical portion of curved root canals. Oral Surg 1995;79 (4): 492-6.

Balanced force technique produced a cleaner apical portion than step-back or crown-down-pressureless technique. Apical portion of the canal was less clean than the middle and coronal portions regardless of the technique.

Recapitulation

The sequential reentry and reuse of previous instruments that have been confirmed to reach the working length in order to prevent packing of debris and dentinal mud at the apical portion of the canal preparation. Recapitulation aids in the effort to maintain the patency of the apical foramen throughout the process of cleaning and shaping the canal system.



Irrigation

Irrigation flushes out the contents of the canal, including dentinal shavings and pulpal debris; and, along with recapitulation, prevents packing of debris in the canal and enhances debridement.

Apical Clearing

A procedure designed to maximize debridement of the apical one-third in curved canals.

McKendry D. Comparison of balanced forces, endosonic, and step-back filing instrumentation techniques: quantification of extruded debris. J Endodon 1990;16:24-7.

The balanced force technique results in significantly less material being apically extruded as compared to endosonics and step-back techniques.

West JD, Roane JB. Cleaning and shaping the root canal system. In Cohen S, Burns RC (eds). Pathways of the pulp. 7th ed. St. Louis: CV Mosby Company, 1998:255-6.

Keep this wisdom guide in mind when preparing root canals:

1. **Establish a vision** of cleaning, shaping, and three-dimensional obturation as inseparable accomplishments.
2. **Take responsibility** for the outcome. The greatest variable is the clinician.
3. **Clear the mind** by concentrating on each canal separately. Complete coronal shaping early and focus on the apex separately.
4. **Train the team.** When the assistants know how to provide timely and appropriate support, the clinician can focus on the details of the canal system and perfect the cleaning and shaping.
5. **Practice delicacy.** The light touch is the most sensitive and the best eye for visualizing the deep canal anatomy and producing a proper shape.
6. **Time is our ally.** Slow down, practice patience, and find the reward in quicker results. Time spent in obtaining the correct result is saved when retreatment and surgery are avoided. If there is not time to do it right, when will there be time to fix it?
7. **Customize the access** and insist on straight-line entry into the canals.
8. **Keep the dentin chips (mud) in suspension.** Use NaOCl freely and frequently and keep the chamber full at all times.
9. **Visualize the shape.** Shaping is the secret to exceptional obturation. Imagine the obturation and establish the appropriate shape.
10. **Practice efficiency.** Use each instrument to its maximal benefit, not to its maximal possible time or strength. Do not use instruments forcefully. Use light touch and frequent sequencing.
11. **Use new instruments.** It is more profitable to throw away instruments than to lose time with a bent one or try to bypass a separated one. Do not mix and match; continue to use the same type of file throughout an instrumentation procedure.
12. **Remember pulpal anatomy.** Ribbons, sheets, laterals, accessories, cul-de-sac, and bends form complex systems that challenge the best. Always expect four canals in molars, two canals in mandibular incisors, and acute apical bends in most canals.
13. **Produce detailed radiographs.** Demand the exact angulation to obtain maximal detail. Visualize the relationship between the chamber, canal, and furcations. Obtain extra detail and information with multiple preoperative and operative radiographs. Insist on great detail and accuracy in the length determination film. Use the radiographic terminus only for patency.
14. **Do it once and do it well.**